

Pulmonary Auscultation

Bernard Karnath, MD

Michael C. Boyars, MD

Pulmonary auscultation has been a principal feature of standard physical examinations for many years and is a very useful initial noninvasive test for lung diseases. Although the role of the stethoscope in pulmonary auscultation is being challenged by newer technologies, the instrument is still the centerpiece of diagnostic tools for the physician and the most efficient diagnostic medical instrument used to provide clinical cues concerning the etiology of dyspnea, a common presenting symptom in the acute care setting. This article briefly discusses the history behind the development of the stethoscope and the current state of the art of pulmonary auscultation. The article also reviews the terminology used to describe breath sounds and discusses several diseases that cause adventitious breath sounds.

HISTORICAL PERSPECTIVE

Rene Laennec developed his original stethoscope in 1816.¹ His first stethoscope was a quire of paper rolled into the form of a cylinder. He originally called the instrument *le cylindre*. Prior to Laennec's invention, direct auscultation by placement of a physician's ear on the chest of a patient was an established practice (Figure 1). However, Laennec noted the following:

Direct auscultation was as uncomfortable for the doctor as it was for the patient. It was hardly suitable where most women were concerned and, with some, the very size of their breasts was a physical obstacle to the employment of this method.²

Laennec first used his original stethoscope on a young woman because her age and sex did not allow him to directly place his ear on her chest.

In 1816 I was consulted by a young woman presenting general symptoms of disease of the heart. Taking a sheaf of paper, I rolled it into a very tight roll, one end of which I placed over the praecordial region, while I put my ear to the other.²

PULMONARY AUSCULTATION

Normal Breath Sounds

Tracheal
Bronchial
Bronchovesicular
Vesicular

Adventitious Breath Sounds

Discontinuous: crackles, pleural friction rubs
Continuous: wheezes, rhonchi, stridor

Laennec studied many different chest sounds. He published his findings in *De L'Auscultation Médiante* in 1819 (Figure 1).²

CURRENT STATE OF THE ART

Today, there is great concern at academic institutions about the lack of proficiency among many medical graduates in performing pulmonary auscultation. A study by Mangione and Nieman evaluating 627 postgraduate trainees from internal medicine and family medicine revealed that all of the trainees recognized less than half of all clinically significant respiratory events via pulmonary auscultation, with little improvement per year of training.³ Additionally, another survey reported that only 10% of US graduate programs offer structured learning in pulmonary auscultation.⁴ However, modern technological advancements (eg, simulated sounds, multimedia, CD-ROMs) allow academic institutions to efficiently teach the art of pulmonary auscultation.^{5,6}

Dr. Karnath is an Assistant Professor of Internal Medicine and Dr. Boyars is a Professor of Medicine, Division of Pulmonary and Critical Care Medicine, University of Texas Medical Branch, Galveston, TX.

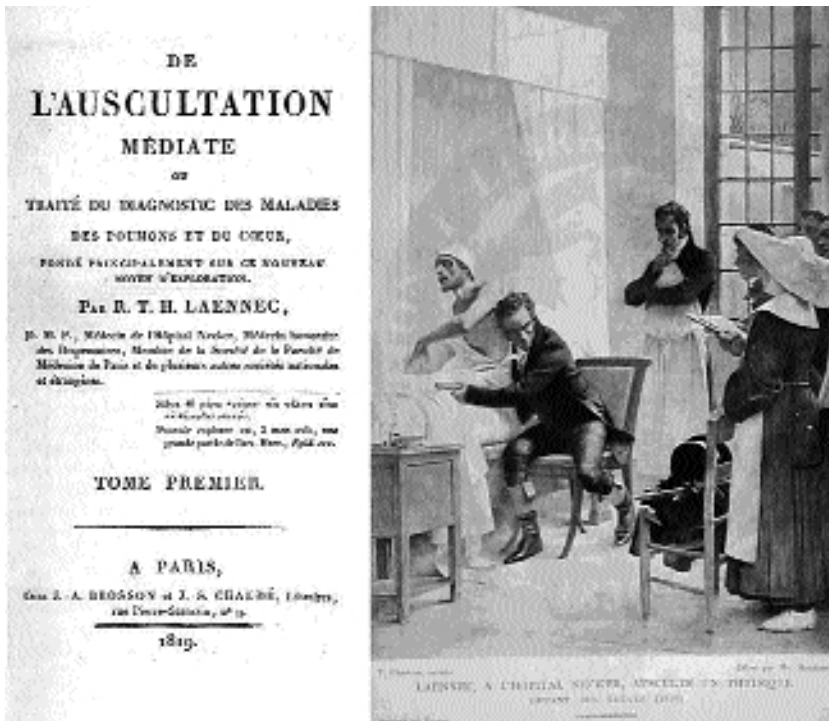


Figure 1. Left, the cover of *De L'Auscultation Médiate* published in 1819. Right, *Laennec à l'Hopital Necker, Ausculte un Physique* (Laennec listening with his ear against the chest of a patient), a portrait by Theobald Chartran. (Reproduced by courtesy of the National Library of Medicine.)

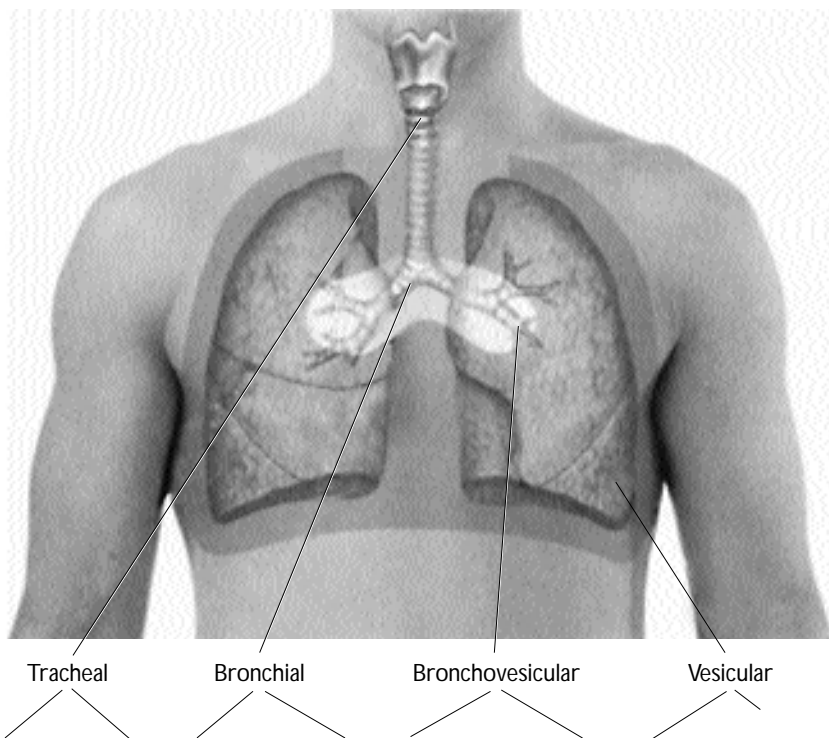


Figure 2. Normal breath sounds. (Adapted with permission from Seidel HM, Ball JW, Dains JE, Benedict GW. *Mosby's guide to physical examination*. 4th ed. St. Louis: Mosby; 1999:79.)

Table 1. Characteristics of Normal Breath Sounds

Feature	Normal Breath Sounds			
	Tracheal	Bronchial	Bronchovesicular	Vesicular
Location	Trachea	Manubrium	Mainstem bronchi	Peripheral lung
Quality	Loud, harsh, hollow	Loud, less harsh, hollow	Soft	Softer
Pitch	Highest	Higher	High	Low
Duration	∕ \	∕ \	∕ \	∕ \

∕ = inspiratory phase; \ = expiratory phase.

Table 2. Adventitious (Extra) Breath Sounds

Discontinuous (nonmusical)

Crackles (generally high-pitched, discontinuous sounds)

Coarse: loud, low-pitched sounds

Fine: soft, high-pitched sounds

Pleural friction rubs (grating sound)

Continuous (musical)

Wheezes (high-pitched sounds that are musical in quality)

Rhonchi (sounds with a “snoring” or “gurgling” quality)

Stridor (sounds heard over the trachea)

BREATH SOUNDS

Breath sounds are generated by turbulent airflow through the respiratory tree. Characterized by their pitch, intensity, qualities (eg, harshness or loudness), and duration (of the inspiratory and expiratory phases), breath sounds should be auscultated with the diaphragm of the stethoscope. The qualities of the breath sounds are modified as they filter through the respiratory tree (Figure 2).

Normal Breath Sounds

Normal breath sounds can be classified as tracheal, bronchial, bronchovesicular, or vesicular (Table 1). Typically, the breath sound auscultated depends on the area of the thorax being examined (Figure 2).

Vesicular breath sounds are soft, low-pitched sounds and can be heard over the periphery of both lung fields; with regard to these breath sounds, the inspiratory phase lasts longer than the expiratory phase. Bronchovesicular breath sounds are soft and high pitched. These sounds are heard best between the scapulae. Bronchial breath sounds are loud, hollow, harsh sounds; they are heard best over the manubrium. Bronchial breath sounds are an abnormal finding if heard in the peripheral lung fields. Lobar consolida-

tion can transmit bronchial breath sounds to the periphery. Tracheal breath sounds are high pitched and loud. They have a tubular quality. Tracheal breath sounds are heard best in the neck region.

Adventitious Breath Sounds

Adventitious breath sounds are superimposed on normal breath sounds and usually indicate disease. Adventitious breath sounds can be classified as continuous or discontinuous. Continuous breath sounds are uninterrupted musical sounds, whereas discontinuous breath sounds are explosive, sharp, discrete bursts of sound. The detection of adventitious breath sounds can help in diagnosing a disorder.

There has been some inconsistency in the use of proper terminology for adventitious breath sounds; these sounds include crackles, wheezes, rhonchi, pleural friction rubs, and stridor (Table 2). Crackles are sometimes referred to as rales; the term rale (and later the term rhonchus) was originally used by Laennec to describe all adventitious pulmonary sounds.⁷ Crackles, wheezes, and rhonchi are the most common adventitious breath sounds.

Crackles are discontinuous adventitious breath sounds and can be classified as fine or coarse. Coarse crackles are loud and low pitched. Fine crackles are soft and high pitched. A crackle is generated when an abnormally closed airway snaps open during inspiration or closes at the end of expiration.⁸ Crackles can also be described based on the timing of the sound during inspiration and expiration (eg, late inspiratory crackles versus early inspiratory crackles). Pleural friction rubs are also discontinuous sounds. Pleural friction rubs are generated when the 2 serous membranes of the pulmonary pleura rub together.

Wheezes and rhonchi are continuous adventitious breath sounds, which are generated by air flowing through a narrowed airway. Wheezes are high pitched

Table 3. Auscultatory Findings in Lobar Consolidation

Auscultatory Finding	Distinctive Characteristic
Bronchial breath sounds	Tubular breath sounds that are transmitted to the periphery
Egophony	Spoken "Ee" heard as "A" when auscultating
Bronchophony	Spoken phrase "99" heard best over the consolidation
Pectoriloquy	Whispered phrase "1, 2, 3" is heard best over the area of consolidation
Crackles	Discontinuous sounds heard on auscultation

continuous musical sounds with a dominant frequency of 400 Hz or more. Rhonchi are also continuous adventitious musical sounds. They are, however, lower pitched and have a snoring or gurgling quality with a dominant frequency of 200 Hz or less.⁹ Rhonchi are the result of secretions in the larger airways; they may clear with coughing. Stridor, also a continuous adventitious breath sound, indicates an obstruction in the trachea or larynx.

CLINICAL CORRELATIONS

Chronic Obstructive Pulmonary Disease and Congestive Heart Failure

Chronic obstructive pulmonary disease (COPD) denotes either a combination of emphysema, chronic bronchitis, and asthma or any one of these disease entities alone. Emphysema is classified as panlobular or centrilobular. In panlobular emphysema, the alveoli and alveolar ducts are destroyed. Patients with panlobular emphysema typically have a hyperinflated chest. In centrilobular emphysema, the respiratory bronchioles are destroyed. A common auscultatory finding in pulmonary emphysema (panlobular or centrilobular) is a reduction of lung sounds, which is predominantly due to airflow limitation.¹⁰

In chronic bronchitis, there is excessive bronchial mucus production most often caused by cigarette smoking; rhonchi are commonly auscultated. Also, early inspiratory crackles are characteristic of chronic bronchitis, whereas midinspiratory and expiratory crackles are characteristic of bronchiectasis. Chronic bronchitis causes wheezes, as well.

Asthma is characterized by bronchial hyperreactivity leading to edema of the bronchial walls. Edema of the bronchioles cause a narrowing of the airway caliber,

USEFUL WEB SITES FOR LEARNING PULMONARY AUSCULTATION

<http://www.rale.ca/LungSounds.htm>
<http://www.music.mcgill.ca/auscultation/auscultation.html>
<http://www.wilkes.med.ucla.edu/lungintro.htm>

thus providing the mechanism for wheezing.^{11,12}

Exacerbation of congestive heart failure and asthma are two common causes of acute dyspnea. On pulmonary auscultation, physicians most often record fine inspiratory crackles for patients with congestive heart failure and wheezes for patients with asthma.¹³ (However, medium and coarse crackles are also encountered in cases of congestive heart failure.) The crackles of congestive heart failure occur at all times during inspiration (paninspiratory) but usually occur late in inspiration.¹⁴

However, crackles associated with congestive heart failure and wheezes associated with asthma are not specific findings for the diseases.¹⁵ For example, in a study by Epler et al, 60% of patients with interstitial lung disease had fine crackles on lung auscultation, and 10% to 12% of patients with COPD had fine crackles on lung auscultation.¹⁶

Likewise, other conditions such as congestive heart failure can be associated with wheezing (hence the term "cardiac asthma"¹⁷). In fact, asthma is a rare cause of new-onset wheezing in elderly patients. A new onset of asthma occurs in only 3% of patients older than 60 years. It has been emphasized that cardiac asthma is more likely to occur in elderly patients and to be misdiagnosed as another disease entity in this group.¹⁷

Lobar Pneumonia

Common auscultatory findings in lobar pneumonia are outlined in **Table 3**. A study of 24 patients with radiographically proven lobar pneumonia found that the auscultatory findings with the highest sensitivity were crackles, bronchial breath sounds, and egophony.¹⁸ A common finding in lobar pneumonia, egophony can be defined as a change in pronunciation of a sound. Egophony can be checked by asking the patient to say, "Ee" and auscultating for its transformation to "A."¹⁹ The crackles of lobar pneumonia are almost always paninspiratory and coarse in description. In addition, continuous adventitious sounds (wheezes and rhonchi) can also be present. These findings typically occur in the area of consolidation.

Interstitial Lung Disease

Pulmonary fibrosis is a common interstitial restrictive lung disease. The most common auscultatory finding for patients with pulmonary fibrosis is late inspiratory fine crackles. A study evaluating the incidence of crackles in 272 patients with interstitial pulmonary disease found that 60% had bilateral fine crackles on lung auscultation.¹⁶ The crackles in pulmonary fibrosis differ from the crackles produced by other diseases, such as congestive heart failure, in that they are much shorter in duration.⁸

Pleural Effusions

Pleural effusions are common complications of post-coronary artery bypass grafting and diseases such as congestive heart failure, nephrotic syndrome, and cirrhosis. The most common auscultatory finding is decreased breath sounds. In some cases of pleural effusion, the lung may be upwardly displaced, causing compression of the lung at the top of the effusion, leading to a consolidation of the lung. Additional auscultatory findings just above the effusion may include bronchial breath sounds and egophony.

CONCLUSION

Pulmonary auscultation is an integral part of physical examinations. With an understanding of the terminology used in pulmonary auscultation and proper tools for learning the technique, it should not become a lost art. With advances in technology, the teaching of pulmonary auscultation can be performed more efficiently. **HP**

REFERENCES

1. Sakula A. RTH Laennec 1781-1826. His life and work: a bicentenary appreciation. *Thorax* 1981;36:81-90.
2. Carmichael AG, Ratzan RM. *Medicine: a treasury of art and literature*. New York: Hugh Lauter Levin Associates; 1991.
3. Mangione S, Nieman LZ. Pulmonary auscultatory skills during training in internal medicine and family practice. *Am J Respir Crit Care Med* 1999;159(4 Pt 1):1119-24.
4. Mangione S, Loudon RG, Nieman LZ, Fiel SB. Lung auscultation during internal medicine and pulmonary training: a nationwide survey. *Chest* 1993;104:70S.
5. Mangione S, Nieman LZ, Gracely EJ. Comparison of

- computer-based learning and seminar teaching of pulmonary auscultation to first-year medical students. *Acad Med* 1992;67(10 Suppl):S63-5.
6. Seidel HM, Ball JW, Dains JE, Benedict GW. *Mosby's guide to physical examination*. 4th ed. St. Louis: Mosby; 1999.
7. Andrews JL Jr, Badger TL. Lung sounds through the ages. From Hippocrates to Laennec to Osler. *JAMA* 1979;241:2625-30.
8. Piirila P, Sovijarvi AR. Crackles: recording, analysis and clinical significance. *Eur Respir J* 1995;8:2139-48.
9. Meslier N, Charbonneau G, Racineux JL. Wheezes. *Eur Respir J* 1995;8:1942-8.
10. Schreur HJ, Sterk PJ, Vanderschoot J, et al. Lung sound intensity in patients with emphysema and in normal subjects at standardised airflows. *Thorax* 1992;47:674-9.
11. Bobear JB. Obstructive airway disease. Clinical cues to diagnosis and management. *Postgrad Med* 1976;60:177-85.
12. Loudon R, Murphy RL Jr. Lung sounds. *Am Rev Respir Dis* 1984;130:663-73.
13. Pearson SB, Pearson EM, Mitchell JR. The diagnosis and management of patients admitted to the hospital with acute breathlessness. *Postgrad Med J* 1981;57:419-24.
14. Bettencourt PE, Del Bono EA, Spiegelman D. Clinical utility of chest auscultation in common pulmonary diseases. *Am J Respir Crit Care Med* 1994;150(5 Pt 1):1291-7.
15. Mulrow CD, Lucey CR, Farnett LE. Discriminating causes of dyspnea through clinical examination. *J Gen Intern Med* 1993;8:383-92.
16. Epler GR, Carrington CB, Gaensler EA. Crackles (rales) in the interstitial pulmonary diseases. *Chest* 1978;73:333-9.
17. Braman SS, Davis SM. Wheezing in the elderly. Asthma and other causes. *Clin Geriatr Med* 1986;2:269-83.
18. Wipf JE, Lipsky BA, Hirschmann JV, et al. Diagnosing pneumonia by physical examination: relevant or relic? *Arch Intern Med* 1999;159:1082-7.
19. Sapira JD. About egophony. *Chest* 1995;108:865-7.

SUGGESTED READING

Boyars MC. Chest auscultation: how to maximize its diagnostic value in lung disease. *Consultant* February 1997;37:415-24.

Test your knowledge and comprehension of this article with Review Questions on [page 41](#).