

# Demystifying Direct Laryngoscopy and Intubation

*Richard M. Levitan, MD*

*Scott D. Cook-Sather, MD*

*E. Andrew Ochroch, MD*

**D**irect laryngoscopy with a rigid laryngoscope is the primary method of tracheal intubation and is a fundamental resuscitation skill. According to the Office of Cardiovascular Care Programs of the American Heart Association (personal communication, October 1988), this procedure is taught to more than 330,000 persons annually in the United States as part of certification for advanced cardiac life support. Direct laryngoscopy has a very high success rate in both the operating room and the emergency department. In the operating room, the failed intubation rate is approximately 35 in 10,000 cases, or 0.035%.<sup>1</sup> In the emergency setting, multiple studies have reported success rates of 99% or greater.<sup>2-5</sup>

Despite these statistics that demonstrate widespread instruction and high rates of success, direct laryngoscopy is still regarded as uniquely difficult. Although health care providers are trained to intubate with a laryngoscope, many are not comfortable with the procedure. This paradox is explained by numerous studies showing that novice intubators have low initial success rates. Emergency medical technicians, paramedics, and physicians all have initial intubation success rates of 50% or less.<sup>6-8</sup> In a study of anesthesia trainees, the mean success rate for the first 10 intubation attempts was approximately 45%, and skill acquisition did not plateau until 57 attempts.<sup>8</sup>

This article reviews the difficulties in learning direct laryngoscopy. A new technology, the Airway Cam direct laryngoscopy video system (Airway Cam Technologies, Inc., Wayne, PA), is discussed, and a stepwise approach to the procedure is presented. In addition, figures are provided to illustrate the technique.

## DIFFICULTIES IN LEARNING

Numerous aspects of direct laryngoscopy—some of which are dependent on how the procedure is taught and some of which are inherent to the procedure—

contribute to the complications of learning the procedure. These aspects include current teaching approaches, limited opportunities for practice, restricted visualization and monocularity during intubation, and the lack of photodocumentation of the procedure.

## Teaching Approaches

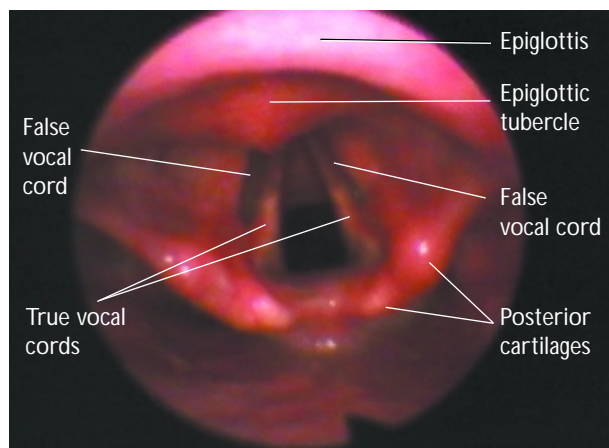
Traditional teaching of direct laryngoscopy involves practice on a training manikin and reference to line drawings of anatomic landmarks. Manikins, however, are built for durability and lack a realistic tongue and epiglottis, the two structures that interact the most with the laryngoscope. In addition, neither a manikin nor a line drawing displays the variability in appearance of laryngeal structures found in real patients.

## Limited Opportunities for Practice

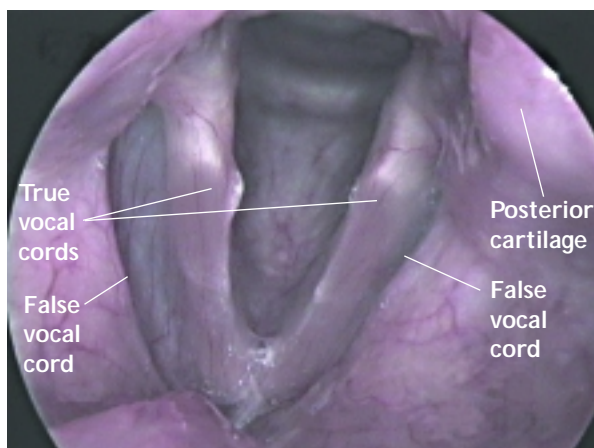
With the exception of opportunities for anesthesia personnel, practice opportunities on patients in the controlled setting of the operating room are limited. In addition, the increasing use of the laryngeal mask airway for elective surgery may be decreasing intubation opportunities in the operating room. Although commonly performed in the past, use of recently deceased patients to practice intubation is no longer considered ethically acceptable.<sup>9</sup> The clinical setting, whether in the operating room or in an emergency situation, is very stressful for the trainee. Intubation must occur quickly, whether because of paralytic agents, respiratory failure, or cardiac arrest. In most settings, trainees are warned in advance that they have only one

---

*Dr. Levitan is Assistant Professor and Attending Physician, Department of Emergency Medicine, and Dr. Ochroch is Assistant Professor, Department of Anesthesiology, Hospital of the University of Pennsylvania, Philadelphia, PA. Dr. Cook-Sather is Assistant Professor of Anesthesia, University of Pennsylvania School of Medicine, and Assistant Anesthesiologist, The Children's Hospital of Philadelphia, Philadelphia.*



**Figure 1.** Fiberoptic view of the larynx through a diagnostic rhinolaryngoscope. The epiglottis is apparent at the top of the image, but the edge of the epiglottis is not visible. At the base of the epiglottis is the epiglottic tubercle. Coming down from the epiglottis to the posterior cartilages are the aryepiglottic folds. The difference between the true vocal cords (vocal ligaments) and false vocal cords (vocal folds) is apparent. Figure courtesy of Richard M. Levitan, MD. Reprinted with permission from Airway Cam Technologies, Inc., Wayne, PA.



**Figure 2.** View of the larynx as seen with a stroboscopic rigid laryngoscope. This view of the larynx is upside down compared with the view during direct laryngoscopy. At the top of the image, the tracheal rings can be seen between the posterior cartilages. The true and false vocal cords are also shown. Figure courtesy of Richard M. Levitan, MD. Reprinted with permission from Airway Cam Technologies, Inc., Wayne, PA.

opportunity for intubation before a supervisor performs the procedure.

#### **Restricted Visualization and Monocularity**

The inherently difficult aspect of direct laryngoscopy is that the procedure is visually analogous to looking down a narrow pipe at a target the size of a quarter. The opening of the mouth, the tongue, epiglottis, and laryngoscope blade all interact to restrict visualization of the larynx to the dominant pupil. Procedural texts teach that a binocular view of the larynx can be achieved by keeping the left arm straight and maintaining a relatively far distance away from the patient's mouth.<sup>10,11</sup> Although most laryngoscopists keep both eyes open during the procedure, when the visual input from each eye is alternatively restricted, the monocular nature of the procedure can be appreciated.<sup>12</sup> Four out of five persons use the right eye to sight the larynx during laryngoscopy.<sup>12</sup> This statistic reflects the facts that eyedness follows handedness and 80% to 90% of persons are right handed. Also, the common laryngoscope designs (Macintosh, Miller, and Wisconsin) all have a left-sided flange for directing the tongue leftward. The resultant view down the mouth is along the right paralingual space. Persons with glasses and left-hand dominance are more likely to use their left eye to sight the larynx.<sup>12</sup>

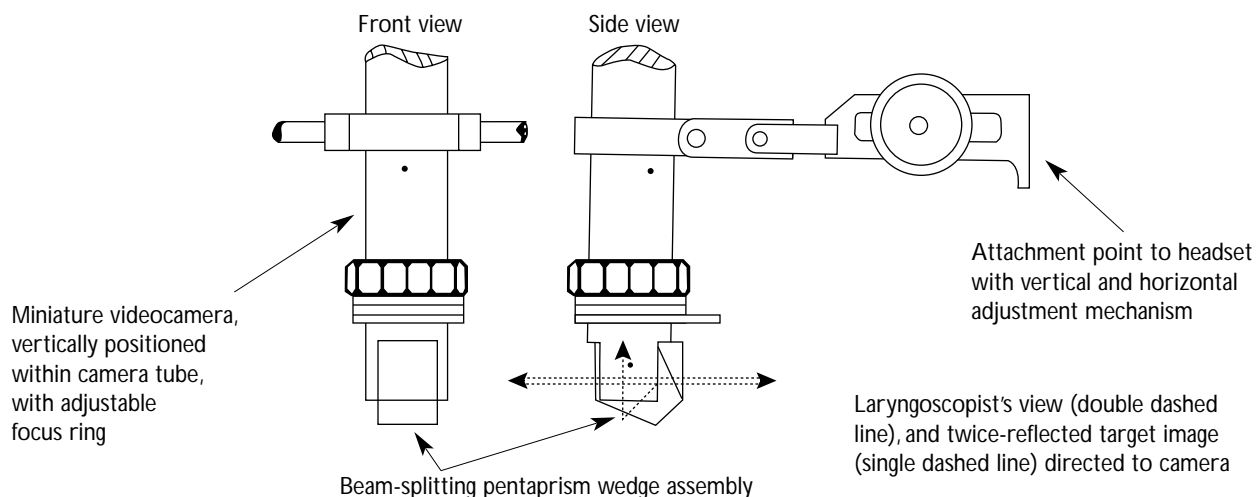
The monocular nature of laryngoscopy means that the procedure cannot be effectively observed over someone else's shoulder. A supervisor cannot provide targeted feedback to a trainee because they both cannot simultaneously visualize the laryngeal structures. Likewise, if the trainee fails, the supervisor cannot effectively demonstrate the procedure to the trainee.

#### **Lack of Photodocumentation**

In addition to the multiple factors already discussed that complicate learning laryngoscopy, one final aspect must be noted: the procedure has not been traditionally photodocumented from the perspective of the laryngoscopist. No photographs of the procedure as it appears to the laryngoscopist are available in any resuscitation, anesthesia, or emergency medicine reference texts. Diagnostic imaging of the larynx is routinely performed with sophisticated stroboscopic laryngoscopes and flexible fiberoptic devices, but these images do not correlate with what is actually seen during direct laryngoscopy (**Figures 1 and 2**). In direct laryngoscopy, not only is the view more restricted, but the structures are smaller and upward traction on the laryngoscope blade distorts laryngeal anatomy.

#### **Proposed Solutions**

To address some of the teaching and supervisory



**Figure 3.** Optical path of the Airway Cam direct laryngoscopy video system. Figure courtesy of Airway Cam Technologies, Inc., Wayne, PA.

challenges of direct laryngoscopy, several authors have proposed attaching a fiberoptic scope to a rigid laryngoscope blade.<sup>13,14</sup> This solution, however, results in an intra-oral fiberoptic view of the larynx and does not correlate with what the laryngoscopist sees. Head-mounted cameras, positioned between the eyes, are commonly used in major teaching hospitals to display surgical procedures but these cameras do not work for laryngoscopy because of the monocularity of the procedure.

#### THE AIRWAY CAM

The Airway Cam direct laryngoscopy video system, invented in 1994, is a head-mounted video device with a monocular sighting mechanism that can image the procedure of direct laryngoscopy from start to finish.<sup>15</sup> The original design used a standard pentaprism that was attached to a vertically mounted miniature video camera on a pair of goggles. A pentaprism was used to reflect the target image through two reflections, thus correcting the left-right orientation for the camera. The design has been modified recently with a beam-splitting pentaprism wedge assembly, and the device is now mounted to an adjustable headset.<sup>16</sup> The optical path of this device is shown in **Figure 3**. The beam-splitting prism allows the laryngoscopist to sight directly through the prism at the target, as shown in **Figure 4**. The video signal can be displayed on a monitor for real-time display as well as recorded.

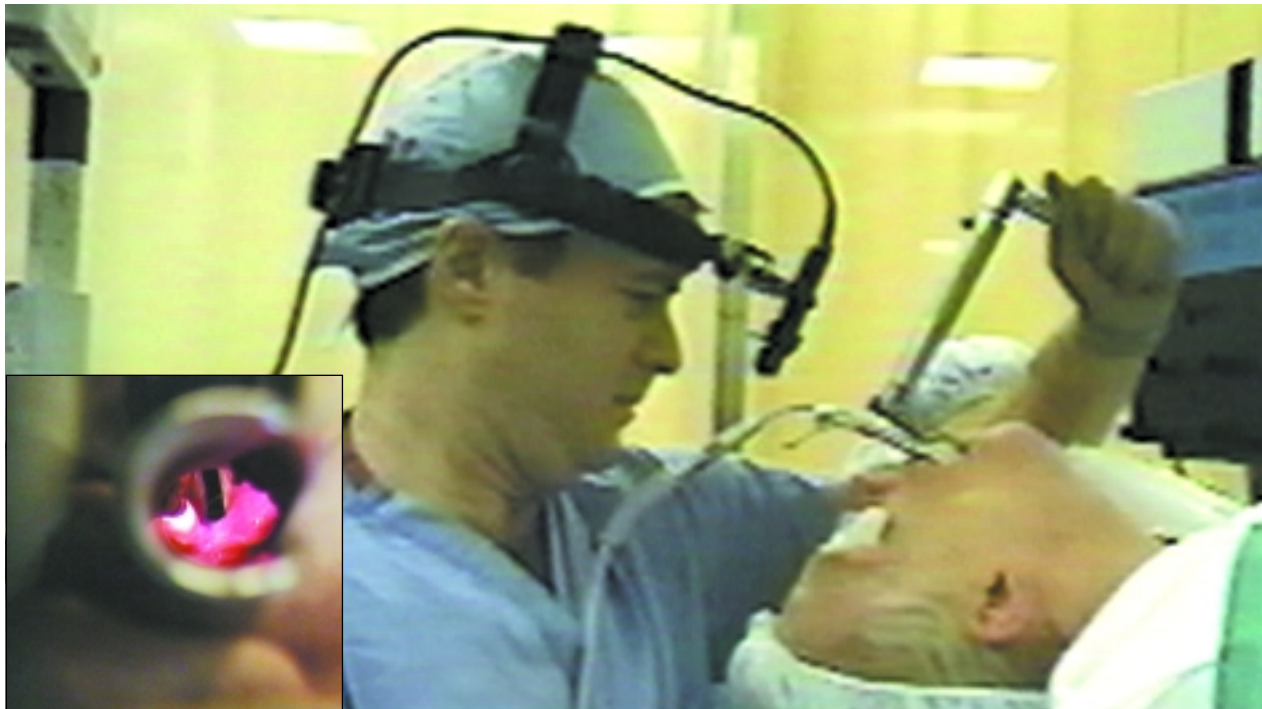The device can be worn by the trainee to demonstrate to the supervisor what exactly the trainee is seeing.<sup>17,18</sup> This system allows targeted feedback and enables the supervisor to perform minor interventions

to assist the trainee without taking over the procedure. Examples of these interventions include retracting the upper right lip, manipulating the external larynx, and providing additional upward leverage on the laryngoscope. With the use of telemedicine technology and long-range transmission, visual observation and two-way audio communication can occur off site.<sup>19</sup> For students and other trainees rotating through the operating room, the system allows them to effectively observe the procedure. For paramedics, residents, or nurse practitioners, in whom documentation of airway management skills is required, the device allows them to record all of their intubation attempts, and the resultant videotape can serve as a visual record of basic competence.

As of April 1999, 10 Airway Cam systems were in use in the United States, and three commercially available videotapes have been made with the device.<sup>20-23</sup> In the future, a large library of direct laryngoscopy images will be available through videotapes, compact disks, and print media as well as the Internet. The authors of this article expect that photodocumentation of intubation will become as routine a part of training as a manikin is currently.

#### A STEPWISE APPROACH

The following steps to direct laryngoscopy and intubation apply to patients who are deeply comatose or in cardiac arrest (**Table 1**). The steps of laryngoscopy as mentioned omit the use of pharmacologic adjuncts. The Airway Cam device can be used to image any laryngoscopy, but patients who are not deeply comatose or in cardiac arrest may not have relaxed jaws and may bite



**Figure 4.** Photograph of the Airway Cam direct laryngoscopy imaging system seen from the lateral perspective during laryngoscopy. Note the alignment of the operator's eye, the camera, and the target. Inset) The larynx as seen during direct laryngoscopy with a Wisconsin blade. Reprinted with permission from Airway Cam Technologies, Inc., Wayne, PA.

**Table 1.** Steps for Direct Laryngoscopy and Intubation

Preparation (SOAPME)

- Suction
  - Oxygen
  - Airway equipment (tracheal tube, oral airway, laryngoscope)
  - Positioning and pre-oxygenation
  - Monitors (cardiac monitor and pulse oximetry)
  - Esophageal detection device (end-tidal carbon dioxide detector, esophageal bulb, or syringe aspiration device)
- Proper positioning of the patient
- Opening the patient's mouth
- Control of the tongue
- Control of the epiglottis
- Landmark identification
- Passage of the tracheal tube

as the intubator's fingers are inserted in the patient's mouth. (The Airway Cam does not assist intubation—this device solely enables imaging and supervision.) Although induction agents and muscle relaxants are

commonly used by anesthesiologists and emergency physicians, these agents are not appropriate for use by novice intubators and are beyond the scope of this article. The process of direct laryngoscopy and intubation as seen using the Airway Cam is illustrated in **Figures 5 and 6.**

**Preparation**

Prior to beginning the procedure, the proper equipment must be assembled. A mnemonic for remembering the necessary equipment is SOAPME:

S = suction

O = oxygen

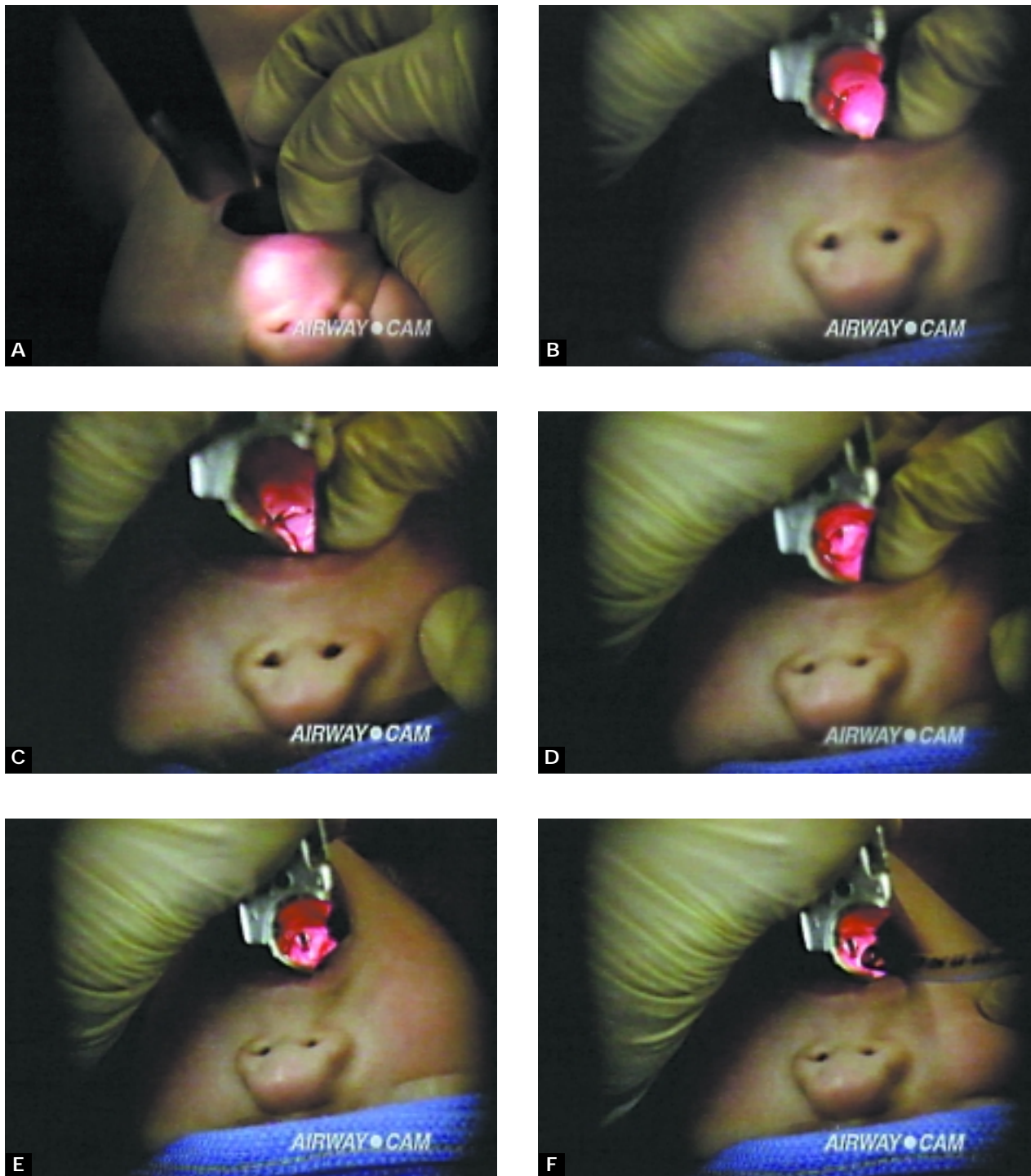
A = airway equipment (tracheal tube, oral airway, laryngoscope)

P = positioning and pre-oxygenation

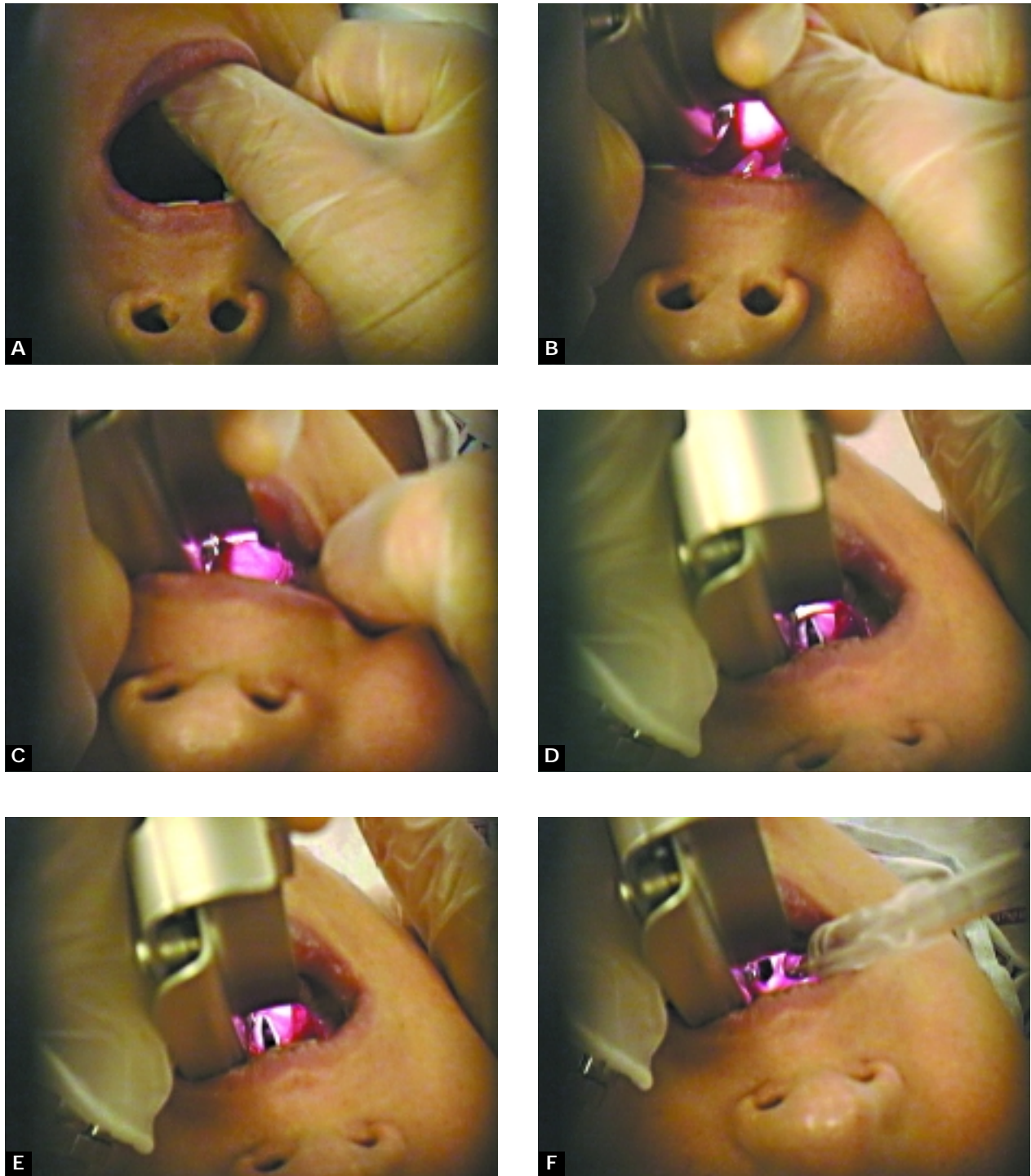
M = monitors (cardiac monitor and pulse oximetry)

E = esophageal detection device (end-tidal carbon dioxide [CO<sub>2</sub>] detector, esophageal bulb, or syringe aspiration device)

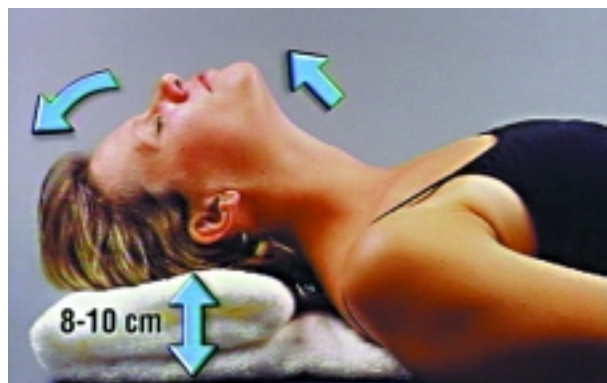The laryngoscope light should be checked before use, and the cuff on the tracheal tube should be inflated,



**Figure 5.** Intubation sequence using a Wisconsin 2 blade in a 6-year-old child. A) The scissor technique is used to open the mouth, B) the posterior pharynx is visualized, C) the edge of the epiglottis and the hypertrophied tonsils are seen, D) the posterior cartilages and a portion of the glottis are visible but the vocal cords are not seen, E) the true vocal cords, glottic opening, and posterior cartilages are visualized, and F) a cuffless tracheal tube is inserted from the right side. Figure courtesy of Scott D. Cook-Sather, MD. Reprinted with permission from Airway Cam Technologies, Inc., Wayne, PA.



**Figure 6.** Intubation sequence using a modified Macintosh blade in a young woman. A) The scissor technique is used to open the mouth, B) the uvula and posterior pharynx are visualized, C) the brightly lit edge of the epiglottis comes into view, D) the glottis with the epiglottis elevated indirectly by the tip of the curved blade is visualized, E) further lifting with the laryngoscope blade elevates the epiglottis out of view, and F) a cuffed tracheal tube is inserted from the right side. Figure courtesy of E. Andrew Ochroch, MD. Reprinted with permission from Airway Cam Technologies, Inc., Wayne, PA.



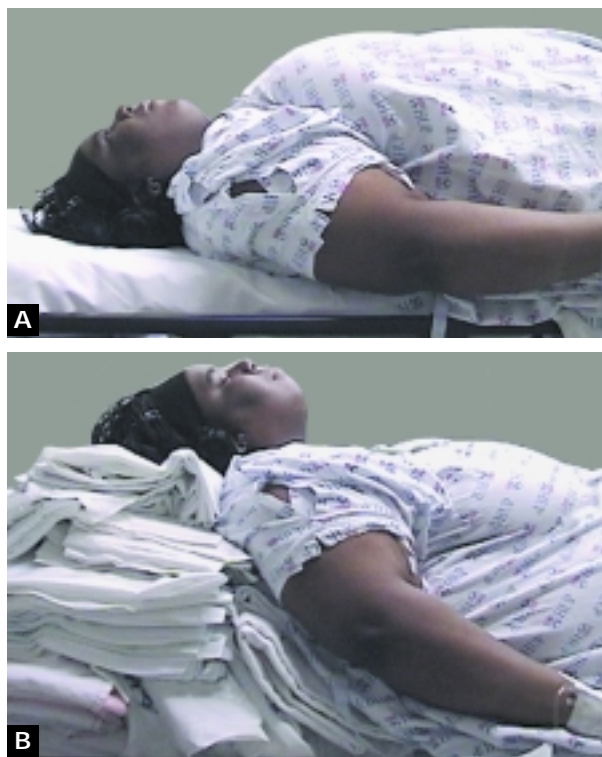**Figure 7.** Ideal head positioning for laryngoscopy on an adult patient involves slight head elevation (neck flexion) and extreme atlanto-occipital extension. Figure courtesy of Richard M. Levitan, MD. Reprinted with permission from Airway Cam Technologies, Inc., Wayne, PA.

checked for leaks, and fully deflated. A malleable stylet, fashioned in the shape of a hockey stick, is generally recommended for emergency cases. The stylet should never extend beyond the tip of the tracheal tube.

#### Proper Positioning of the Patient

Failure to properly position the patient is a common mistake of novice intubators. Direct laryngoscopy involves direct sighting of the larynx by displacing the tongue and epiglottis with the laryngoscope. Achieving this goal requires alignment of the oropharyngeal, pharyngeal, and laryngeal axes. Atlanto-occipital extension and slight neck flexion is the ideal position for alignment of the axes. This position is possible to attain by elevating the patient's head 8 to 10 cm and tilting the head backwards as far as possible (Figure 7). This position is also known as the *sniffing position*. The sniffing position is also advantageous for ventilating the patient prior to intubation.

In emergency situations, proper positioning is often overlooked. The laryngoscopist sometimes compensates for this deficit by lifting the patient's head off of the bed with the laryngoscope. The human head weighs 8 to 10 lbs, and, in obese patients, such lifting of the head and shoulders may be impossible. Figure 8 shows the proper positioning for an obese patient. The sniffing position is contraindicated in patients with known or suspected cervical spine injury, in which case laryngoscopy is performed with an assistant maintaining in-line stabilization. In infants and small children, the large size of the occiput in relation to the body already results in slight neck flexion when the patient



**Figure 8.** A) Morbidly obese patient in a supine position. Laryngoscopy is impossible because of the inability to lift the patient's head and shoulders. B) Proper alignment of axes for laryngoscopy in obese patients requires a massive amount of support under the head and shoulders (sheets and towels are used to support this patient). Figure courtesy of Richard M. Levitan, MD. Reprinted with permission from Airway Cam Technologies, Inc., Wayne, PA.

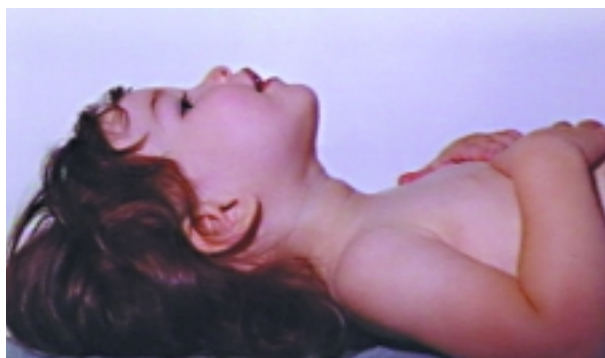is laying supine. Head elevation is not required nor beneficial in these patients (Figure 9).

#### Opening the Patient's Mouth

After proper positioning of the patient, the next step is opening the patient's mouth. Opening the patient's mouth is most easily accomplished by a scissor technique involving the laryngoscopist's thumb and middle finger of the right hand. Inserting fingers between the teeth of semiconscious or comatose patients can be dangerous (Figures 5A and 6A).

#### Control of the Tongue

Because the scissor technique is performed on the right side of the patient's mouth (Figures 5A and 6A), the initial insertion of the laryngoscope blade is directed from left to right. Upon complete insertion of the blade, however, the flange of the blade should



**Figure 9.** The larger occiput in a young child patient causes the neck to be slightly flexed even without any additional head elevation. Head elevation and extreme atlanto-occipital extension are not recommended in infants and young children for laryngoscopy. Figure courtesy of Richard M. Levitan, MD. Reprinted with permission from Airway Cam Technologies, Inc., Wayne, PA.

completely control the tongue and direct it to the left side of the patient's mouth. This technique is facilitated by slight rotation of the laryngoscopist's wrist in a counterclockwise direction.

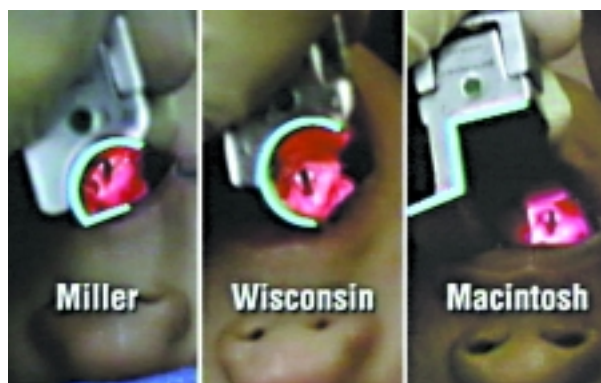
For most laryngoscopists, the curved blade (Macintosh blade) is much easier to use than the straight blade for two reasons. First, the curved blade fits the shape of the tongue and has a natural stopping point in the vallecula. Second, the curved blade has a larger flange that enables easier control of the tongue. The straight blade (Miller blade) has a smaller working area to visualize the laryngeal structures and less space to place the tracheal tube without obscuring visualization of the target. Compared with the D-shaped small arc of the Miller blade, the Wisconsin blade is a straight blade with a more round arc and a larger lumen down the barrel of the blade (**Figure 10**).

Inadequate control of the tongue is a frequent mistake of novice intubators. Inadequate control causes the tongue to flop over both sides of the blade and reduces the area for both visualization and placement of the tracheal tube.

#### Control of the Epiglottis

The laryngoscope blade should be advanced steadily along the tongue until the epiglottis is identified. A common mistake of novice intubators is to advance the blade too far and become lost in the tissues of the posterior pharynx and esophagus. The epiglottis is reliably located at the base of the tongue (Figures 5C and 6C).

With the curved blade (Macintosh), the tip of the blade is placed into the vallecula between the base of the tongue and the epiglottis. Pressure on the hyoepi-



**Figure 10.** Comparative views of the three common blades for laryngoscopy, looking down the lumen of each blade in three pediatric patients. A) The Miller blade has a small D-shaped arc compared with B) the round, larger arc of the Wisconsin blade. C) The Macintosh blade has the largest flange, which has a reversed Z shape. Figure courtesy of Richard M. Levitan, MD. Reprinted with permission from Airway Cam Technologies, Inc., Wayne, PA.

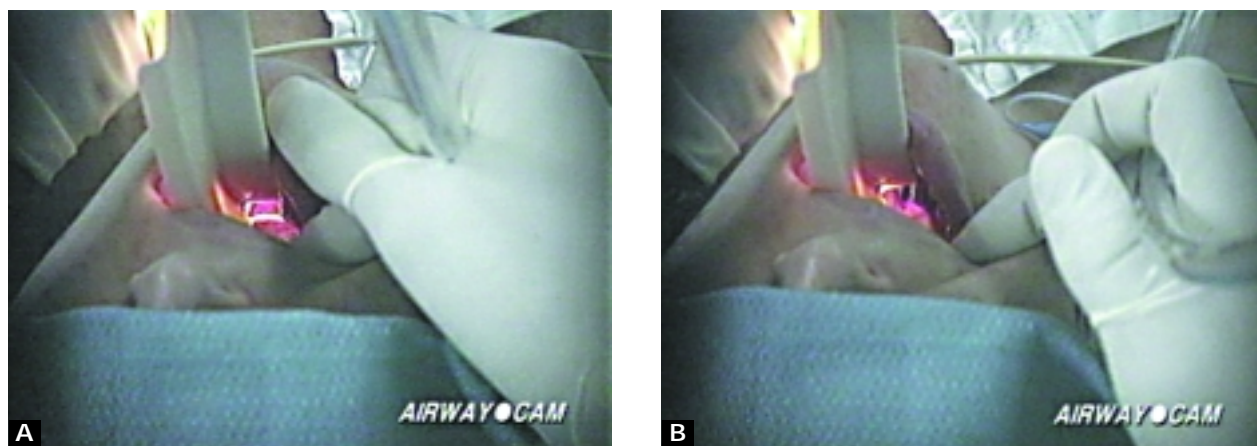glottic ligament causes the epiglottis to be indirectly elevated (**Figure 11**). Levering backwards with the laryngoscope blade brings the tip of the blade out of the vallecula and worsens the laryngeal view, in addition to potentially causing dental trauma.

The epiglottis is directly elevated with the tip of the blade when a straight blade (Miller or Wisconsin) is used. The direction of the lifting force on the laryngoscope is always at 45 degrees or parallel to the handle of the laryngoscope (**Figure 12**). If the patient has been properly positioned before intubation, the amount of lifting force required is minimal.

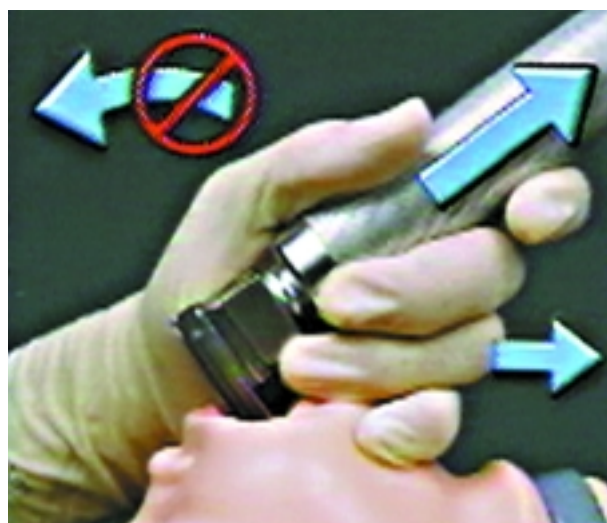#### Landmark Identification

Beyond the epiglottis, one of two structures should come into view. Ideally, the larynx is identifiable by visualization of either the true vocal cords or the prominences of the posterior cartilages (Figures 5D-E, 6D-E, and 11B). The true vocal cords are white and usually unmistakable, although infection, edema, and secretions can obscure their recognition. The posterior cartilages comprise the cuneiform and corniculate cartilages; positioned most posteriorly and midline is the interarytenoid notch. These structures distinguish the larynx from the entrance into the esophagus, even when the vocal cords are not definitively identified (**Figure 13**).

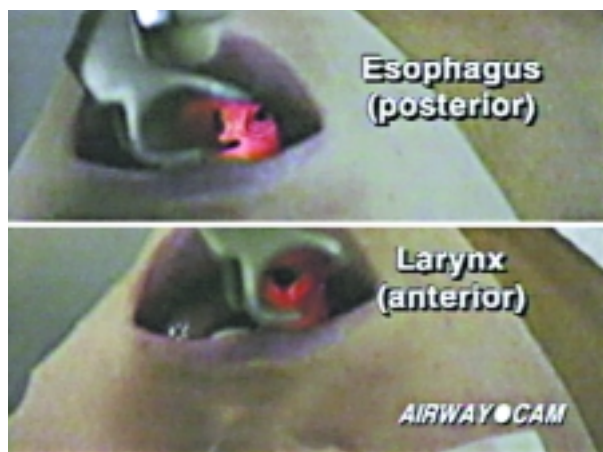
The dark glottic opening usually has a narrow vertical shape because of the upward force from the laryngoscope. Depending on the degree of glottic exposure, illumination by the blade, and shadowing by the epiglottis, the larynx has a variety of appearances. The esophagus is



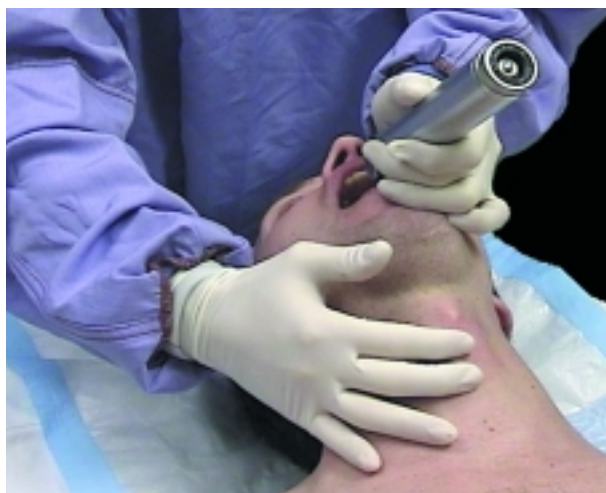**Figure 11.** Use of a Macintosh blade for control of the epiglottis during laryngoscopy. A) The brightly lit edge of the epiglottis is visualized as a Macintosh blade is inserted in a young woman. The laryngoscope should always be steadily advanced down the tongue until the epiglottis is identified. B) With the curved Macintosh blade, pressure on the hyoepiglottic ligament at the vallecula elevates the tip of the epiglottis indirectly. The posterior cartilages and the glottic opening are now visible. The tongue is directed to the left side of the mouth by the large flange on the Macintosh blade. Figure courtesy of Michael S. Higgins, MD. Reprinted with permission from Airway Cam Technologies, Inc., Wayne, PA.



**Figure 12.** The forces involved in laryngoscopy demonstrated on the head of a pediatric manikin. The main lifting force of the laryngoscope is parallel to the handle. Under no circumstances should the handle of the laryngoscope be levered backwards. The handle is gripped down at the base. Figure courtesy of Richard M. Levitan, MD. Reprinted with permission from Airway Cam Technologies, Inc., Wayne, PA.



**Figure 13.** Comparative views of the esophagus and the trachea in the same patient intubated with a straight blade when the true vocal cords are not seen. The interarytenoid notch and the posterior cartilages distinguish the entrance into the trachea. The trachea is anterior to the esophagus. Figure courtesy of Michael S. Higgins, MD. Reprinted with permission from Airway Cam Technologies, Inc., Wayne, PA.



**Figure 14.** External laryngeal manipulation by the laryngoscopist's right hand on the patient's thyroid cartilage.

a round hole without any adjacent structures and is located posteriorly and slightly to the right of midline.

If none of the structures of the larynx can be seen, and the blade is not inserted too deeply, then external pressure on the patient's thyroid cartilage by the laryngoscopist's right hand or by an assistant, may bring the posterior cartilages and glottic opening into view beneath the epiglottis (**Figure 14**).<sup>24,25</sup>

#### Passage of the Tracheal Tube

The tracheal tube should always be introduced and advanced towards the target from the right side (Figures 5F and 6F). Placing the tube in the line of sight to the target blocks the view and can lead to esophageal placement. If the tube is not readily seen passing between the vocal cords, the tip should be observed to pass anterior to the interarytenoid notch and posterior cartilages.

Tracheal tubes have a standard length of 30 cm. In code situations, it is not uncommon for the tube to be advanced too far. The tube should be stabilized at the lip line, and the centimeter markings along the tube should be checked. The depth of insertion at the lip line should be 23 cm for men and 21 cm for women.

Auscultation alone is not a reliable way to verify tracheal tube placement. Confirmation of tube placement in the trachea should be achieved by end-tidal CO<sub>2</sub> measurement or an esophageal detection device, and tube placement should be further confirmed by pulse oximetry, an arterial blood gas measurement, and chest radiography. Auscultation of bilateral and symmetric breath sounds in addition to noting the

depth of tube insertion at the lip line are critical for preventing right mainstem intubation.

#### SUMMARY

Direct laryngoscopy is a relatively straightforward procedure in most patients. Novice intubators should pay careful attention to proper positioning and control of the tongue and epiglottis. Whether using straight or curved blades, landmarks should be progressively exposed, starting with the uvula and palatal arch, moving on to the epiglottis and posterior cartilages, and finally to the larynx and glottic opening. The posterior cartilages and interarytenoid notch mark the entrance into the larynx even when the true vocal cords are not seen. External laryngeal manipulation by the laryngoscopist's right hand may make these structures visible in cases of difficult laryngoscopy.

Manikin practice can help with hand-eye coordination, but a thorough familiarity of the appearance of laryngeal structures on live patients is essential for mastering laryngoscopy. Traditionally this experience has involved operating room practice, although direct laryngoscopy imaging can facilitate initial intubation success. A recent study of novice intubators in the operating room found that mean initial intubation success rates improved from 46% to 88% by adding video imaging to manikin training.<sup>26</sup> Direct laryngoscopy imaging is expected to become a common component of intubation training in the future. **HP**

#### NOTE

Dr. Levitan owns patent and trademark rights to the Airway Cam direct laryngoscopy video system and the name Airway Cam, and he is a principal in Airway Cam Technologies, Inc., Wayne, PA.

#### REFERENCES

1. Benumof JL: Definition and incidence of the difficult airway. In *Airway Management: Principles and Practice*. Benumof JL, ed. St. Louis: Mosby, 1996:121-125.
2. Sakles JC, Laurin EG, Rantapaa AA, Panacek EA: Airway management in the emergency department: a one-year study of 610 tracheal intubations. *Ann Emerg Med* 1998; 31:325-332.
3. Calderon Y, Gennis P, Martinez C, Gallagher EJ: Intubations in an emergency medicine residency: the selection and performance of intubators [Abstract]. *Acad Emerg Med* 1995;2:411-412.
4. Tayal VS, Riggs RW, Marx JA, et al: Rapid-sequence intubation at an emergency medicine residency: success rate and adverse events during a two-year period. *Acad Emerg Med* 1999;6:31-37.
5. Vissers RJ, Barton ED, Sagarin MJ, et al: Success and

(continued on page 59)

(from page 56)

- complication rates of rapid-sequence vs non-rapid-sequence intubation in 1,200 emergency intubations [Abstract]. *Acad Emerg Med* 1998;5:481.
6. Konrad C, Schupfer G, Wietlisbach M, Gerber H: Learning manual skills in anesthesiology: is there a recommended number of cases for anesthetic procedures? *Anesth Analg* 1998;86:635-639.
  7. Sayre MR, Sakles JC, Mistler AF, et al: Field trial of endotracheal intubation by basic EMTs. *Ann Emerg Med* 1998;31:228-233.
  8. Stewart RD, Paris PM, Pelton GH, Garretson D: Effect of varied training techniques on field endotracheal intubation success rates. *Ann Emerg Med* 1984;13:1032-1036.
  9. Morhaim DK, Heller MB: The practice of teaching endotracheal intubation on recently deceased patients. *J Emerg Med* 1991;9:515-518.
  10. Roberts JR, Hedges JR: *Clinical Procedures in Emergency Medicine*, 2nd ed. Philadelphia: WB Saunders, 1991:12.
  11. Benumof J, ed: *Airway Management: Principles and Practice*. St. Louis: Mosby, 1996:265-272.
  12. Levitan RM, Higgins MS, Ochroch EA: Contrary to popular belief and traditional instruction, the larynx is sighted one eye at a time during direct laryngoscopy [Letter]. *Acad Emerg Med* 1998;5:844-846.
  13. Woodard JM, White SJ, Wrenn KD: Use of the intubating fiberoptic as a tool to safely teach and supervise endotracheal intubation [Abstract]. *Acad Emerg Med* 1997;4:50.
  14. Morales GA, Gilbert TB: An aid for simultaneous instructor and trainee viewing of orotracheal intubation. *Anesthesiology* 1991;74:1173-1174.
  15. Levitan RM: A new tool for teaching and supervising direct laryngoscopy. *Acad Emerg Med* 1996;3:79-81.
  16. Levitan RM: Direct laryngoscopy imaging: teaching and research applications. Educational Synopses in Anesthesiology and Critical Care Medicine: The Online Journal of Anesthesia. June 1998. Available at: <http://gasnet.med.yale.edu/esia/1998/june/samart.html>. Accessed March 2, 2000.
  17. Higgins MS, Deshpande JK, Badr A: New video system improves teaching of direct laryngoscopy [Letter]. *Anesthesiology* 1996;84:1010-1011.
  18. Mackenzie C: Direct laryngoscopy video system [Media review]. *Anesth Analg* 1998;86:921.
  19. University of Maryland School of Medicine, Advanced Telemedicine and Technology Program. Available at <http://www.umm.edu/anesthesia/research/ATTP/airway.html>. Accessed March 2, 2000.
  20. Doyle J: Video review: orotracheal intubation. Produced by Levitan RM, Higgins MS. *Can J Anaesth* 1998;45:288.
  21. Bryan JH: Airway Cam Video Series, volume 1: orotracheal intubation [Media review]. Produced by Levitan RM, Higgins MS. *Acad Emerg Med* 1997;4:130.
  22. Gutstein HB: Pediatric intubation, volume 2 of Airway Cam Video Series [Media review]. Produced by Levitan RM, Cook-Sather S. *Anesth Analg* 1999;89:808.
  23. Flamik DE: Airway Cam, direct laryngoscopic video system, volumes 1 and 2 [Media review]. Produced by Levitan RM, Higgins MS. *Ann Emerg Med* 1999;34:418-419.
  24. Benumof JL, Cooper SD: Qualitative improvement in laryngoscopic view by optimal external laryngeal manipulation. *J Clin Anesth* 1996;8:136-140.
  25. Takahata O, Kubota M, Mamiya K, et al: The efficacy of the "BURP" maneuver during a difficult laryngoscopy. *Anesth Analg* 1997;84:419-421.
  26. Levitan RM, Goldman TS, Bryan DA, Herlich A: Training with video imaging improves the initial intubation success rate of paramedic trainees in an OR setting. In press.

Copyright 2000 by Turner White Communications Inc., Wayne, PA. All rights reserved.